

# Rotator Cuff Injury in Performance Dogs

By Sherman O. Canapp, Jr., DVM, MS, Diplomate ACVS and Ria Acciani, MPT

© DIANELEWISPHOTOGRAPHY.COM

One of the most common forelimb conditions that presents to VOSM in our canine patients is medial shoulder instability (MSI). This condition may be considered similar to a rotator cuff injury in people. Signs of MSI may be as subtle as performance-related problems such as refusing tight turns or be as severe as a weight-bearing lameness. MSI involves multiple components of the shoulder joint and requires a thorough orthopedic evaluation and diagnostic tests to confirm the condition. It is important to identify and treat this condition early to obtain the best long-term results and prevent further shoulder instability and osteoarthritic progression. The recommended diagnostic test for this condition is a shoulder arthroscopy. This minimally invasive procedure allows for complete evaluation of the shoulder joint while performing dynamic testing. Most importantly, if MSI is identified during the evaluation, it can be treated at the same time arthroscopically. If

arthroscopic treatment is performed, dogs will be placed in a shoulder protection device (hobbles or sling, depending on the severity) to protect the shoulder as it heals. Dogs are then placed in a rehabilitation therapy program over the next few months. Recovery following MSI treatment ranges from four to five months with dogs returning to competition by approximately six months.

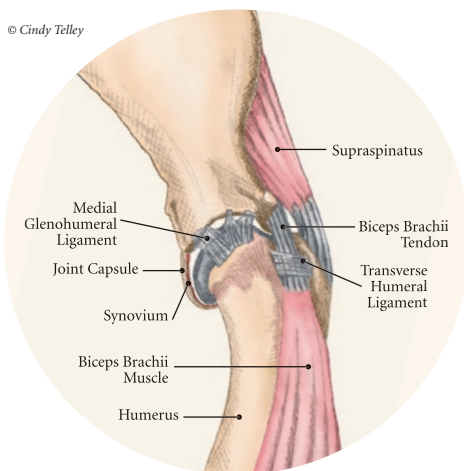
## Anatomy

Anatomically, the canine shoulder joint is the least stable joint, relying on soft tissue structures for stability and function. In dogs the glenohumeral joint (shoulder) has the widest range of motion and is capable of movements in any direction, but its primary movements during ambulation are flexion and extension. The glenohumeral joint relies heavily on capsuloligamentous support to provide stability because its anatomic conformation does not provide a stable socket. The humeral head and glenoid cavity of the

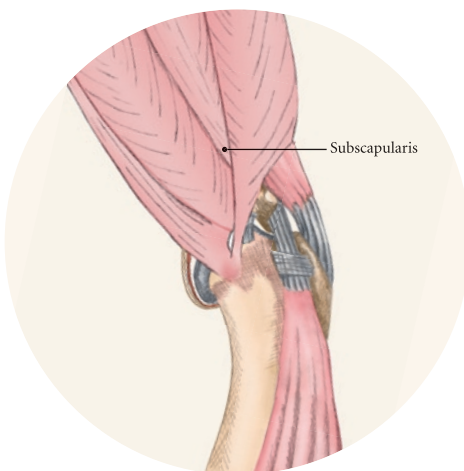
scapula make up the ball and socket of the shoulder joint. The glenoid provides little coverage of the humeral head. The joint capsule, ligaments, and surrounding muscles and tendons all contribute to the stability of the shoulder. Insult or injury to any portion of the capsuloligamentous support structures can potentially cause shoulder joint pathology resulting in pain and dysfunction. The components that are most commonly effected by MSI include the joint capsule, medial glenohumeral ligament, subscapularis tendon, supraspinatus tendon, and less commonly biceps tendon shown in **Figures 1 and 2**. Depending on the severity and chronicity of the instability, the cartilage may also be affected.

## Pathogenesis

Currently, the exact cause of MSI in dogs is unknown, although it is suspected to be related to chronic repetitive activity, or overuse rather than trauma. Overuse of the shoulder support structures leads to



**Figure 1:** Normal anatomy of the medial aspect of the canine shoulder.



**Figure 2:** Normal shoulder anatomy medial aspect demonstrating the subscapularis muscle and tendon unit.

degeneration of the tissues, lowering the tensile strength of the tissues predisposing them to fraying, disruption, and eventually complete breakdown.

Sporting athletes that participate in activities such as agility, undergo extreme stresses on their muscles, ligaments, and tendons. Repetitive activities such as jump-turn combinations and weave poles are performed regularly during practice and at weekend trials. These routine maneuvers place the shoulder near its end range of abduction (movement away from the midline of the body) as shown in **Figure 3**, and stress the soft tissues of the medial shoulder complex. Additionally, events such as slipping on wet surfaces, mishaps on the dogwalk, teeter, or A-frame may also contribute to the trauma inflicted on the shoulder while participating in agility. Over time, there may be a cumulative effect of the micro trauma occurring to the ligaments, tendons, and joint capsule, leading to a decrease in performance.



**Figure 3:** Weaving places the shoulder near its end range of abduction, stressing the soft tissues of the medial compartment.

### History and Clinical Signs

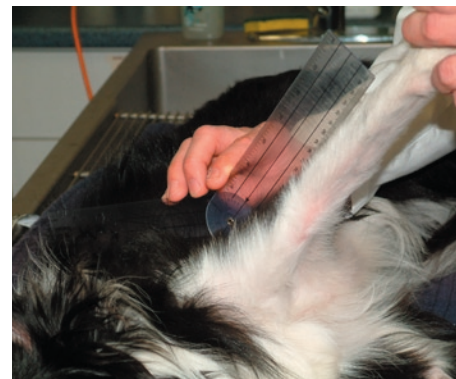
Dogs with MSI may present with varying degrees of history and clinical signs. The history may range from dogs that are missing cues or refusing tight turns during performance to dogs with intermittent unilateral forelimb lameness. It is not uncommon for the dog to have a history from therapists (rehabilitation therapists, massage therapists or chiropractors) that identifies restrictions, spasm and trigger points, or mild atrophy in the affected shoulder during routine sessions. The history of dogs with more chronic conditions typically includes a lack of response to rest and non-steroidal anti-inflammatory drugs (NSAIDs), and dogs that are commonly worse after exercise and heavy activity.

### Orthopedic Examination

Gait analysis may range from a mildly shortened stride in the affected forelimb at a walk and a trot to a significant weight-bearing lameness. Depending on the chronicity, atrophy may be noted in the affected shoulder on physical examination. Forelimb circumference may be decreased in the affected forelimb when compared to the contralateral unaffected forelimb. Dogs with MSI typically have a restriction and decreased range of motion in extension. When placing the shoulder into abduction (moving the shoulder away from the midline of the body), spasm and discomfort are almost always noted. In more severe cases, a slight “thud” or subluxation can often be felt when abducting the shoulder.

If a concurrent supraspinatus tendinopathy is present pain may be noted when placing the shoulder into flexion (direct stretch of the supraspinatus) or on direct palpation of its point of insertion.

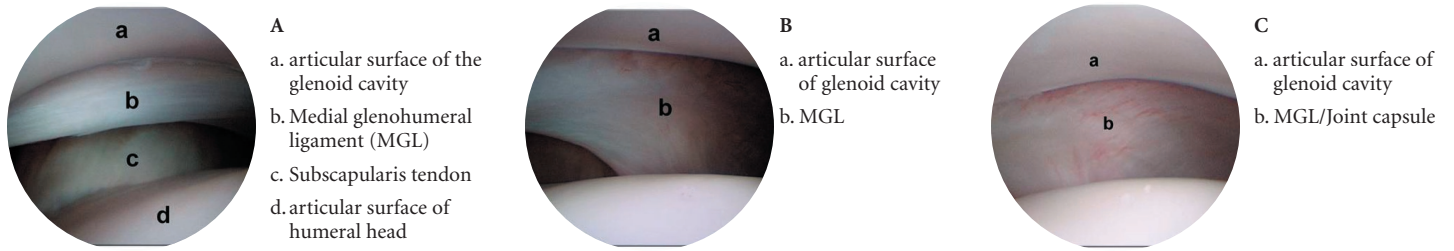
Because preoperative diagnosis of MSI is critical for clinical decision making, a palpation technique has been developed that is known as the shoulder abduction test (Cook J., et al, *Vet Surg* 2005). This test aids in assessment of the passive stabilizers of the medial aspect of the shoulder joint. Using this palpation technique, it has been reported that a normal mean shoulder abduction angle is approximately 30°. The abduction angles in shoulders with MSI are typically significantly larger. In addition, the abduction angles in affected shoulders are typically significantly larger than the contralateral unaffected shoulders in dogs with unilateral MSI. Because MSI is typically a unilateral problem, comparison of the maximal abduction angle between limbs can be diagnostic for unilateral MSI.



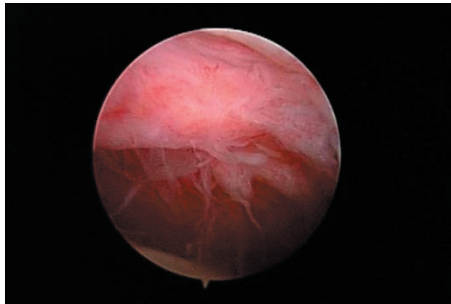
**Figure 4:** Shoulder abduction angle test being performed on a Border Collie with MSI.

To perform the shoulder abduction test dogs are sedated and positioned in lateral recumbency on an examination table. A goniometer is held such that one arm of the goniometer runs parallel to the spine of the scapula so that the center of rotation of the goniometer was centered over the shoulder joint and the free arm of the goniometer extends over the axis of the humerus in contact with the skin. With the elbow and shoulder held in extension, the forelimb is abducted to its physiologic limit and the measurement obtained as shown in **Figure 4**. The dog is then rotated so that the procedure may be performed for the contralateral shoulder.

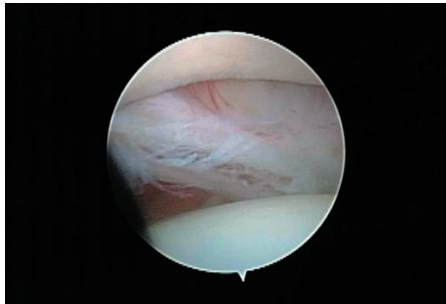
**Figure 5: Normal arthroscopic findings.**



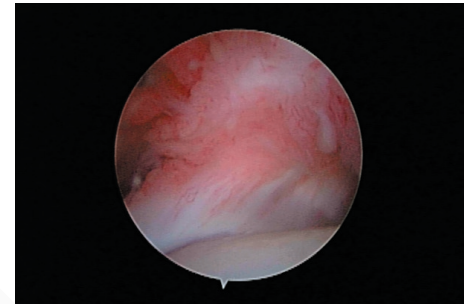
**Figure 6: Arthroscopic findings in a dog's shoulder with MSI.**



*Severe synovitis and joint capsule hypertrophy  
Compare to C:b above*



*Medial Glenohumeral ligament fraying.  
Compare to A:b and B:b above*



*Subscapularis tendon disruption and hypertrophy  
Compare to A:c above*

## Diagnosics

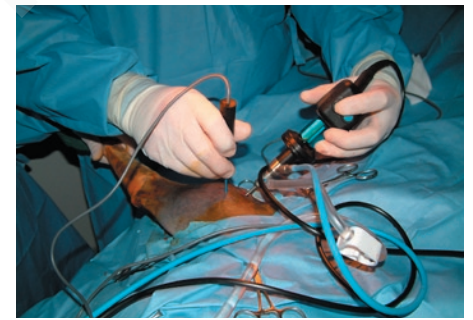In addition to history, signalment, gait analysis, physical examination, orthopedic and neurologic examinations, and abduction angle tests, further diagnostic tests used to differentiate causes of shoulder pathology currently consist of hematology, biochemical profile, urinalysis, arthrocentesis, imaging modalities, and arthroscopy. Arthroscopic evaluation of the shoulder joint allows for direct observation of all major intra-articular structures with magnification, “dynamic” evaluation of tissues during shoulder range-of-motion tests, and “palpation” of intra-articular tissues using arthroscopic instrumentation. Arthroscopic exploration with evaluation of intra-articular structures provides a definitive diagnosis of MSI as shown in **Figures 5 and 6**.

## Treatment

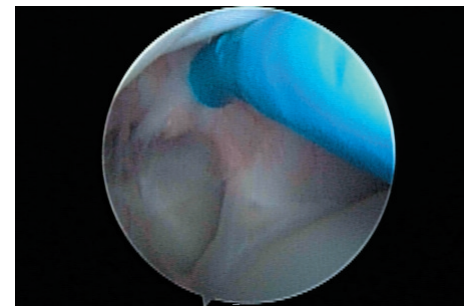
Based on the results of the orthopedic examination, abduction angle tests, and arthroscopic scoring, patients are placed into one of three treatment categories; mild, moderate, or severe. Patients with abduction angles of 35° to 45° and arthroscopic findings consisting of mild pathology (inflammation without fraying, disruption, or laxity of the MGL, subscapularis tendon, joint capsule) are placed in a shoulder support system/hobbles (www.Dogleggs.com) and entered into a rehabilitation therapy program.

Dogs with moderate pathology (moderate category) typically have abduction angles that range from 45° to 65°, and arthroscopic findings consisting of fraying, disruption, and laxity of the subscapularis tendon, medial glenohumeral ligament, focal synovial proliferation associated with the subscapularis tendon, and synovial hypertrophy or hyperplasia. Additional findings may occasionally include a bulge of the suraspinatus tendon with biceps impingement. Dogs in the moderate category are treated arthroscopically with thermal capsulorrhaphy (radiofrequency treatment) and/or imbrication.

Following radiofrequency treatment (RF) and imbrication dogs are placed in a shoulder support system/hobbles like those shown in **Figure 8** for two to three months and entered into a rehabilitation therapy program. Following RF treatment, treated tissues become weaker than pretreatment levels before they get stronger and must be protected. Human studies show that tissues may stretch out if exposed to physiologic loads too early. Tissue may require protection for as long as three months. The balance is between too much immobilization, which results in joint stiffness and muscle contracture, and insufficient immobilization, which results in stretching of the treated tissues and recurrent laxity. Recovery for dogs in the moderate category ranges from three to four months with return to training occurring at four to six months.



**Figure 7: Arthroscopic radiofrequency being performed on a dog.**



**Figure 8: A Border Collie in the shoulder support system (hobbles) following surgery.**

Dogs with severe MSI typically have shoulder abduction angles greater than 65°. Arthroscopic findings usually include complete tears of the medial glenohumeral ligament and severe disruption and the supscapularis tendon and joint capsule. For this type of injury, reconstruction of the medial compartment by direct tissue reapposition and synthetic capsulorrhaphy may be indicated. Following surgical repair, dogs are placed in a custom non-weightbearing velpeau sling for two to four weeks followed by the shoulder support system (hobbles) for two to three months. Rehabilitation therapy is required for a longer period of time since recovery following primary reconstruction ranges from four to six months. Fortunately, severe cases are less common and are usually due to trauma rather than repetitive activities as seen in the mild and moderate categories.

## Postoperative Care

Appropriate postoperative care is a critical factor in dogs with MSI treated with RF treatment. Based on tissue strength data, it is imperative to protect the shoulder during the initial postoperative period. Therefore, dogs are kept in a shoulder protection device (hobbles) for a minimum of three months, especially following RF therapy. It is well documented that collagenous tissues undergoes loss of mechanical properties for two to four weeks after RF treatment. Fibroblast proliferation, infiltration, and synthesis begin to restore these mechanical properties to a functional level in the subsequent weeks if mechanical stimulation of the treated tissues is maintained at appropriate levels. In other words, the tissues treated with RF get weaker before they get stronger and must be protected until sufficient fibroplasia occurs so that

the tissue can resist joint function while maintaining their new length. During the period that the limb is in a protected position (limiting excessive range of motion), it is vital that careful attention to hobble and limb management is ensured.

## Rehabilitation Therapy

Physical therapy for orthopedic conditions has a strong scientific background in human medicine. Many studies have shown the benefits of rehabilitation following rotator cuff surgery. The canine rehabilitation therapist should be aware of and apply what is known to be effective in human practice. Many of the same goals, strategies, and techniques will be applied. Be aware that not all exercises work for every patient; some exercises will require trial and error to achieve desired results. 🐾

*Dr. Canapp, a Diplomate of the American College of Veterinary Surgeons, completed a combined D.V.M./M.S. at Kansas State University, an internship in small animal medicine and surgery at the University of Missouri, a three-year residency in small animal surgery at the University of Florida, and training in canine rehabilitation by the Canine Rehabilitation Institute. Dr. Canapp currently practices orthopedic surgery and sports medicine at the Veterinary Orthopedic & Sports Medicine Group (VOSM) in Ellicott City, Maryland, and acts as a consultant to local zoos, police K-9 units, agility, flyball, and disc competition dogs. See additional information about Dr. Canapp at [www.vetsportsmedicine.com](http://www.vetsportsmedicine.com).*

*Ria Acciani, MPT, and David Acciani, PT, licensed physical therapists with over 25 years of combined experience in field of rehabilitation, own and operate the Advanced Canine Rehabilitation Center in Warren, New Jersey, a practice specializing in assessing, conditioning, and rehabilitating performance dogs. After finishing the Canine Rehabilitation Certificate Program offered by the University of Tennessee, they are now working toward an advanced Masters degree in Animal Physiotherapy from the University of Queensland, Australia.*

Because he's not just a pet.  
**He's an athlete.**



Veterinary Orthopedic and Sports Medicine Group (VOSM) is committed to providing the highest quality veterinary Orthopedic surgery and rehabilitative care. VOSM is the only practice in North America with a:

- Board Certified Veterinary Orthopedic Surgeon trained in Canine Rehabilitation
- Veterinarian and Physical Therapist also trained in Canine Rehabilitation
- Veterinary Sports Trainer

Through the effective integration of science, compassion, and professional integrity, we relieve pain, regain movement, restore function, and promote health and wellness in your flourishing athlete. **We not only understand the demands that are placed on your athlete, we help him meet them.**

- Sports Medicine
- Minimally Invasive Orthopedic Surgery
- Gait Analysis & Retraining
- Rehabilitative Therapy

Entrust your best friend with the best in medical care.



10270 Baltimore National Pike Ellicott City, MD 21042 301-560-1397 or 410-418-8446 [www.vetsportsmedicine.com](http://www.vetsportsmedicine.com)